

OSTEOARTICULAR TUBERCULOSIS OF THE WRIST (Case Report)

Pınar Borman¹, Hürrem Bodur², Hatice Bodur¹, Kenan Bayrakçı³, Uğur Günel³, Selda Seçkin⁴

SUMMARY

Osteoarticular tuberculosis (TB); is an infrequent form of the disease and monoarthritis of the wrist accounts for 1% of all cases of skeletal involvement. Herein, we describe a 71-year-old man presented with progressive right wrist pain and swelling, worsened for the last 9 months. The past medical history was nonspecific and chest x-ray was normal. Laboratory findings were normal except moderate elevation of ESR and CRP levels. He had a strong PPD reaction with 17 mm induration. The radiographs of the wrist illustrated typical features for TB. He had an arthrodesis and the synovial pathology showed granulomatous synovitis. He was started on anti-TB chemotherapy and improved significantly. The differential diagnosis of this rare condition was discussed with the review of the literature.

Key Words: Osteoarticular tuberculosis, monoarthritis, therapy.

ÖZET

EL BİLEĞİNDE OSTEOARTİKÜLER TÜBERKÜLOZ

Osteoartiküler tüberküloz (TB) hastalığının nadir rastlanan bir formudur ve el bileği monoartriti, iskelet tutulumu olan vakaların %1'ini oluşturmaktadır. Burada, travma sonrası sağ el bileğinde ağrı, şişlik ve hassasiyet gelişen ve son 9 aydır semptomları kötüleşen 71 yaşında bir erkek hasta sunulmaktadır. Geçmiş tıbbi öyküsünde özellik olmayan ve akciğer grafisi normal olan hastanın orta derecede ESR ve CRP yüksekliği dışındaki laboratuvar bulguları da normal bulundu. Hastanın 17 mm endurasyon tarzında şiddetli bir PPD reaksiyonu mevcuttu. El bileği grafilerinde TB için karakteristik bulgular izlendi. Artrodez uygulanan hastanın sinovyal patolojisinde grnülomatöz sinovit saptandı. Hastaya anti-TB kemoterapi başlandı ve hasta belirgin olarak düzeldi. Bu nadir hastalığın ayırıcı tanısı, literatür gözden geçirilerek tartışıldı.

Anahtar Kelimeler: Osteoartiküler tüberküloz, monoartrit, tedavi

INTRODUCTION

Osteoarticular tuberculosis (TB); is an infrequent form of the disease and accounting for 1-5% of all cases (1,2). Peripheral joints are the most uncommon site of infection and presents as a low-grade chronic, progressive local infection with a paucity of systemic manifestations and most frequently in the hip or knee (3). Unawareness of the existence of this disorder and the absence of distinct sign and symptoms often lead to considerable delay in diagnosis and treatment (1,4).

We describe a patient with right wrist monoarthritis who was diagnosed as TB osteoarthritis and representing a number of features typical for the condition.

Clinical History

A 71-year-old man presented with progressive left wrist pain and swelling, following a trauma two years earlier, in which he had fallen on his left upper extremity. He had been seen by a physician three

¹ Numune Training and Research Hospital, II. Clinic of Physical Medicine and Rehabilitation

² Numune Training and Research Hospital, II. Clinic of Infectious Diseases

³ Numune Training and Research Hospital, IV. Clinic of Orthopedics and Traumatology

⁴ Numune Training and Research Hospital, Department of Pathology

months after the trauma. At that time he had little swelling without erythema and mild pain on range of motion (ROM) of the left wrist. Radiographs of the wrist was obtained, degenerative changes but no fracture was observed and he was prescribed non-steroidal anti-inflammatory agents. No improvement was obtained and the stiffness and pain were progressively worsened for the last 9 months.

Early medical history was non-significant. He had no history of TB or any immunosuppressive disease. There was no family history of TB infection nor of any rheumatic or autoimmune disease. He had not been immunized with BCG vaccine. Constitutional symptoms such as fever, anorexia, fatigue or weight loss were absent. He was not receiving a regular medication.

When seen in our clinic, the general physical examination was entirely normal. A slight increase in body temperature was present (37.2°C). He had considerable pain and severely restricted range of motion of the left wrist with a fixed ulnar subluxation deformity (Figure 1). The rest of the musculoskeletal examination was normal.

Routine laboratory investigations including biochemical tests, complete blood cell count were all normal apart from an elevated ESR (42 mm/h; nor-

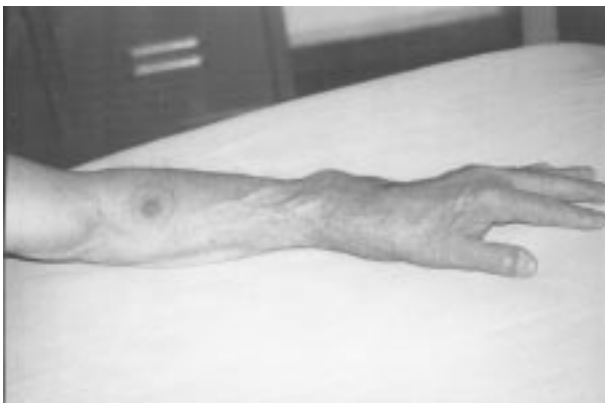

Figure 1: The deformity of the left wrist and the result of the PPD test

mal: <20 mm/h) and CRP (8.93 mg/L; normal: <5 mg/L). Serological tests for ANA and hepatitis viruses were negative. Tumor markers and an HIV test, as well as Brucella antibodies were also negative.

The result of a PPD skin test (5 tuberculin units) was strongly positive with induration 17 mm diameter (Figure 1). His chest x-ray was normal and chest CT showed bilateral peribronchial vascular thickening and minimal fibrotic changes in the right superior lobe, with no evidence of active pulmonary disease.

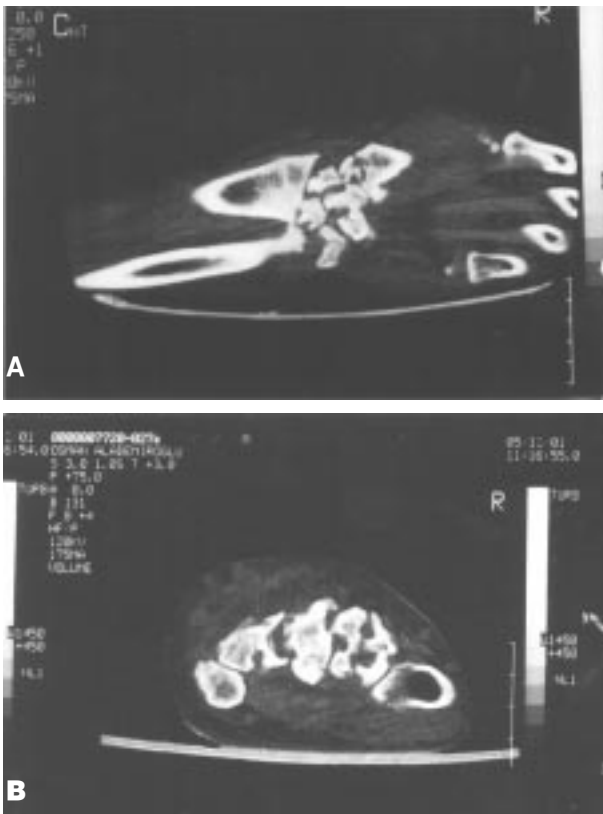
An antero-posterior radiograph of the left wrist indicated soft tissue swelling, joint space loss, gross articular destruction with erosion and cavities through out the carpus, metacarpal bones, ulna and radius. Diffuse osteoporosis of the carpal bones was also observed (Figure 2). A CT scan of the right wrist showed total disappearance of bony trabecula with marked osteoporosis and cortical cysts and associated with erosive sites in the carpal, metacarpal bones, as well as in the ulna and radius. Extensive effusion particularly lobular and in contact with the wrist joint, and a hypodense effusion

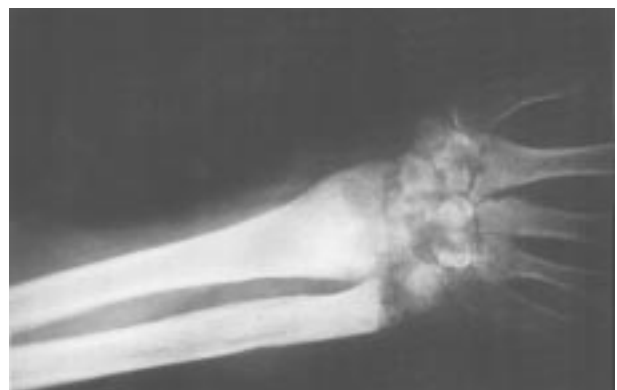

Figure 2: An antero-posterior radiograph of the left wrist indicated soft tissue swelling, joint space loss, gross articular destruction with erosion and cavities through out the carpus, metacarpal bones, ulna and radius, as well as diffuse osteoporosis of the carpal bones.

in radius, which is three centimeters away from the wrist joint, indicating an abscess formation were also observed (Figure 3 A-B).

The abscess cavity was drained. An open synovial biopsy was obtained. Surgical debridement, including proximal row carpectomy, followed by arthrodesis of the left wrist was performed. Cultures for the synovial fluid was negative, whereas synovial biopsy revealed granulomatous synovitis (Figure 4,5).



Figures 3 A-B: A CT scan of the right left showed total disappearance of bony trabecula with marked osteoporosis and cortical cysts and associated with erosive sites in the carpal, metacarpal bones, as well as in the ulna and radius. Extensive effusion particularly lobular and in contact with the wrist joint, and a hipodense effusion in radius, which is three centimeters away from the wrist joint, indicating an abscess formation were also observed.



Figure 4: Granulomas composed of epithelioid histiocytes, lymphocytes and scattered giant cells (HE x 40).

A diagnosis of osteoarticular TB was made depending on the clinical, radiological and pathological findings and he was started on antitubercular treatment with isoniazide, rifampin, pyrazinamide and streptomycin. Over a three-month period; his symptoms and functional disability regressed, ESR returned to normal. He continues to follow-up as an out-patient in the clinics of PMR and Infectious Diseases.

DISCUSSION

Although TB is rarely seen in developed countries, it is still common in developing countries as a ca-

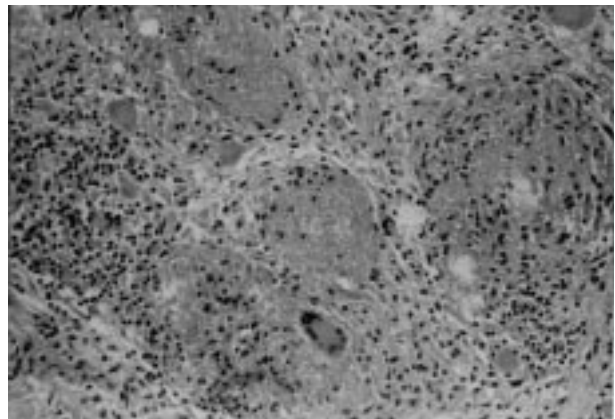


Figure 5: Granulomas with central necrosis and Langhans type giant cell (HE x 200).

use of osteoarticular infection (1,5). TB arthritis most frequently causes a monoarthritis with a predilection for weight-bearing joints such as hip, knee, shoulders or elbow (6). The wrist is an unusual site for osteoarticular TB. Isolated involvement of the wrist is rare and accounts for only 1 % of all cases of peripheral osteoarticular TB (7).

Our case represents a number of typical features for this condition: 1) Only about one third of patients who have osteoarticular TB, have evidence of pulmonary disease and the majority of the cases have normal chest x-rays (4). 2) A history of trauma is commonly followed by inert progressive inflammation, weeks or months later (8). 3) Recent reports suggest a shift to an older population with skeletal involvement in unusual sites accompanied by periarticular abscess formation (9). 4) Constitutional symptoms are usually absent and signs of inflammation are mild (10). 5) Although the symptoms may not be dramatic, chronic infection tends to be progressive and eventually results in radiographically evident destruction of cartilage and bone (1,10). 6) Synovial fluid culture for mycobacteria is positive in only 60-80% of cases and an open synovial biopsy is frequently required to establish the diagnosis of the arthritis in the vast majority of cases (6,10). 7) A positive PPD test result can be helpful in confirming a suspicious TB, but a negative result can not rule it out. 8) The diagnosis is often delayed and surgical intervention may be indicated especially when there is extensive bone and articular destruction (6,11).

Persistent monoarticular inflammation should raise concern about chronic infection or malignancy. The differential diagnosis of this case includes; septic arthritis, lyme arthritis, chronic infection or malignancy. Septic arthritis produces dramatic inflammation followed by irreversible destruction of cartilage and bone.

There are no specific radiographic features that are pathognomic of TB infection of bones and joints and no clinical features that distinguish TB synovitis from other rheumatologic condition such as rheumatoid arthritis or osteomyelitis. Common radiological findings that should arouse suspicion of TB arthritis include, soft tissue swelling with little periosteal reaction and periarticular osteopenia; later joint effusion, narrowing of the joint space, and finally subchondral erosion involving both sides of the joint, cortical irregularity and large areas of cystic osteolysis (6,8,12). Our patient had all these extensive radiological findings. A triad of radiographic findings (Phemister's triad) is characteristic of TB arthritis: Juxtra-articular osteoporosis, peripheral osseous erosion and gradual narrowing of interosseous space (6). CT images also support the diagnosis by demonstrating the irregular disappearance of bony trabecula (12), as seen in our patient. Diagnosis of TB of the peripheral joints requires a high index of suspicion in the elderly (13). Tumors should always be suspected when there is chronic monoarticular inflammation with soft tissue mass and cartilage and bone destruction.

Osteoarticular TB is a treatable condition, with the course and progression resting on early recognition and aggressive treatment (14). Extrapulmonary TB should be managed according to the principles used for pulmonary TB. Initial treatment includes combination therapy with four drugs (isoniazid, rifampin, pyrazinamide and streptomycin or ethambutol) because of frequency to isoniazid resistance. Antimicrobial therapy should be of at least 9 months' duration (6,8,14). Surgical intervention may also be indicated for treatment of intra and extraarticular destruction, large abscess or joint deformity and to restore movement (3,14,15), as performed in our patient. Debridement, curettage and arthrolysis, followed by vigorous physiotherapy are essential to achieve a better ROM (10,11). A prog-

ram of isometric and ROM exercises should be established to preserve muscle development and joint function (10,13).

In conclusion we report a patient who illustrate typical features and the aggressive nature of osteo-

oarticular TB. The possibility of TB should be considered among elderly with chronic progressive monarticular symptoms that do not respond to conventional treatment, to avoid long delay before the diagnosis and to establish the appropriate therapy.

REFERENCES

1. Garrido G, Gomez-Reino JJ, Fernandez-Dapica P, Palenque E, Prieto S. A review of peripheral tuberculous arthritis. *Semin Arthritis Rheum* 1988;18:142-49.
2. Ravigliane MC, Snider DE, Kochi A. Global epidemiology of tuberculosis: Morbidity and mortality of a worldwide epidemic. *JAMA* 1995;273:220-26.
3. Sequeria W, Co H, Block JA. Osteoarticular tuberculosis: current diagnosis and treatment. *Am J Ther* 2000;7:393-8.
4. Gonzalez-Gay MA, Garcia-Porrúa C, Cereijo MJ, Rivas MJ, Ibanez D, Mayo J. The clinical spectrum of osteoarticular tuberculosis in non-human immunodeficiency virus patients in a defined area of northwestern Spain. *Clin Experimental Rheumatol* 1999;17:663-69.
5. Shanahan EM, Hanley SD, Gibney RG, Fitzgerald O. Tuberculosis of the wrist. *Arthritis Rheum* 1999;42:2724-2726.
6. Garcia-Porrúa C, Gonzales-Gay MA, Sanchez-Andrade A, Vazquez-Caruncho M. Arthritis in the right great toe as the clinical presentation of tuberculosis. *Arthritis Rheum* 1998;41:374-75.
7. Turgut M. Spinal tuberculosis (Pott's disease): its clinical presentation, surgical management, and outcome. A survey study on 694 patients. *Neurosurg Rev* 2001;24:8-13
8. Resnick D, Niwayama G. Osteomyelitis, septic arthritis and soft tissue infection:organisms. In Resnick D, Niwayama G (eds). *Diagnosis of bone and joint disorders*. WB Saunders Company, Philadelphia 1995, pp:2448-2558.
9. Haas DW. Mycobacterial diseases. In Mondell GL, Bennet JE, Dolin R (eds). *Principles and Practice of Infectious Diseases*. Churchill Livingstone, Philadelphia 2000, pp:2576-2607 .
10. Watts HG, Lifeso RM. Current concepts review. Tuberculosis of bones and joints. *J Bone Joint Surg Am* 1996;78A:288-99.
11. Chen WS, Wang CJ, Eng HI. Tuberculous arthritis of the elbow. *Int Orthop* 1997;21:367-70.
12. Ergin G, Acunas B, Acunas G, Turaci M. Imaging of extrapulmonary tuberculosis. *Radiographics* 2000;20(2):471-88.
13. Bocanegra TS. Mycobacterial, fungal and parasitic arthritides. In Klippel J, Dieppe P. *Rheumatology*, Mosby, London, 1994;4:5.1-12.
14. Ad Hoc Committee of the Scientific Assembly on microbiology, tuberculosis and pulmonary infections. Treatment of tuberculosis and tuberculosis infection in adults and children. *Clin Infect Dis* 1995;21 :9-27.
15. Ruggieri M, Pavone V, Polizzi A, Smilari P, Fede GF, et al. Tuberculosis of the ankle in childhood : Clinical, Roentgenographic and computed tomography findings. *Clin Pediatr* 1997;62:529-534.