


## Analysis of treatment outcomes in patients with antineutrophil cytoplasmic antibody-associated vasculitis on rituximab therapy

Tsvetelina Yoneva<sup>1</sup> , Yana Zdravkova<sup>1</sup> , Georgi Kotov<sup>1</sup> , Ekaterina Ivanova Todorova<sup>2</sup> ,  
Georgi Vasilev<sup>2</sup> , Rasho Rashkov<sup>1</sup> , Ivan Sheytanov<sup>1</sup> 

<sup>1</sup>*Clinic of Rheumatology, University Hospital St. Ivan Rilski, Sofia, Bulgaria*

<sup>2</sup>*Laboratory of Clinical Immunology, University Hospital St. Ivan Rilski, Sofia, Bulgaria*

### ABSTRACT

**Objectives:** This study aimed to analyze a group of patients with severe and refractory antineutrophil cytoplasmic antibody (ANCA)-associated vasculitis (AAV) managed with rituximab and to report on treatment outcomes.

**Patients and methods:** A total of 78 patients (41 females, 37 males; mean age: 50.1±13.4 years; range, 18 to 76 years) with AAV on rituximab treatment were included in the single-center, retrospective study conducted between 2009 and 2018. The diagnosis was established based on the 1990 classification criteria of the American College of Rheumatology and the definitions of vasculitis of Chapel Hill Consensus Conference. Laboratory and immunological tests were conducted. Disease activity was determined through the Birmingham Vasculitis Activity Score.

**Results:** Rituximab was preferred over cyclophosphamide in 37 patients and used as a second-line therapy after cyclophosphamide in 41 cases. Rituximab treatment showed favorable outcomes with regard to serum creatinine levels, proteinuria, and hematuria, as well as in cases of isolated lung involvement. Nearly half of patients with pulmonary renal syndrome also improved, with 22.2% achieving remission. ANCAs were positive in 85.9% of patients at the onset of rituximab treatment and became negative in 82% of the positive cases. Adverse events were rare and included infusion reactions (one case of reactivation of a herpes zoster infection and one case of allergic reaction).

**Conclusion:** Rituximab is an efficient and safe therapeutic option in patients with AAV who are difficult to treat, have insufficient response, or have not tolerated other treatments.

**Keywords:** Antineutrophil cytoplasmic antibodies, rituximab, vasculitis.

Antineutrophil cytoplasmic antibody (ANCA)-associated vasculitides (AAVs) are multisystem autoimmune diseases characterized by the necrotizing inflammation of small blood vessels and the presence of circulating autoantibodies directed against antigens found in the cytoplasm of neutrophils, such as ANCA, as well as various organ manifestations.<sup>1,2</sup> AAVs include three main types: granulomatosis with polyangiitis (GPA), also known as Wegener's

granulomatosis, microscopic polyangiitis (MPA), and eosinophilic granulomatosis with polyangiitis, also known as Churg-Strauss syndrome. At present, several treatment regimens exist depending on AAV severity. For more than 40 years, the combination of cyclophosphamide and corticosteroids was considered the standard therapy for remission induction in generalized and systemic forms of AAV.<sup>3-5</sup> Recently, the treatment of AAV

**Received:** March 07, 2022 **Accepted:** August 19, 2022 **Published online:** November 04, 2022

**Correspondence:** Tsvetelina Yoneva, MD. Clinic of Rheumatology, University Hospital St. Ivan Rilski, Sofia, Bulgaria.  
E-mail: tz\_yoneva@abv.bg

### Citation:

Yoneva T, Zdravkova Y, Kotov G, Todorova EI, Vasilev G, Rashkov R, et al. Analysis of treatment outcomes in patients with antineutrophil cytoplasmic antibody-associated vasculitis on rituximab therapy. Arch Rheumatol 2023;38(3):397-405.

©2023 Turkish League Against Rheumatism. All rights reserved.

This is an open access article under the terms of the Creative Commons Attribution-NonCommercial License, which permits use, distribution and reproduction in any medium, provided the original work is properly cited and is not used for commercial purposes (<http://creativecommons.org/licenses/by-nc/4.0/>).

has been the subject of multiple studies and analyses aimed at improving disease evolution and prognosis over time.<sup>3-5</sup> The introduction of B cell-targeting therapy for remission induction represents a significant advance in the treatment of these vasculitides and improved prognosis, particularly in patients with refractory disease and those who cannot have cyclophosphamide administered.<sup>6,7</sup> Rituximab is a chimeric monoclonal antibody targeting CD (cluster of differentiation) 20, a surface molecule present on mature B cells, which decreases both the percentage and the absolute number of circulating B cells, as well as those found in granulomas.<sup>8,9</sup> The aim of the present study was to analyze a group of patients with severe and refractory AAV managed with rituximab and report on treatment outcomes.

## PATIENTS AND METHODS

A total of 78 patients (41 females, 37 males; mean age: 50.1±13.4 years; range, 18 to 76 years) with AAV were included in the single-center, retrospective study conducted at the Clinic of Rheumatology at University Hospital 'St. Ivan Rilski' between 2009 and 2018. The diagnosis was established based on the 1990 classification criteria of the American College of Rheumatology (ACR) and the definition of vasculitis of the Chapel Hill Consensus Conference.<sup>1,10</sup> Patients with severe and refractory AAV were included based on the diagnosis of GPA or MPA and needed to have received at least one treatment course of rituximab. The cases that had not achieved remission after at least six months of treatment with cyclophosphamide were considered refractory AAV. Patients with a concomitant autoimmune rheumatic disease and patients with any type of cancer were excluded from the study.

### Study procedures

Laboratory tests were obtained retrospectively. They had been conducted at the time of diagnosis and before the onset of treatment with rituximab in the hospital's clinical and immunological laboratory. They were used to determine disease activity (complete blood count with differential blood count, erythrocyte sedimentation rate, and C-reactive protein), as well as systemic involvement

and severity (creatinine, urea, liver enzymes, urine sediment, proteinuria, and creatinine clearance). The presence of ANCA was demonstrated through indirect immunofluorescence on ethanol-fixed neutrophils and confirmed through enzyme-linked immunosorbent assay for antibodies against proteinase-3 (anti-PR3) and myeloperoxidase (anti-MPO). Demographic, clinical, and laboratory data were collected at the time of the diagnosis and were followed up at six-month intervals. Disease activity was determined through the Birmingham Vasculitis Activity Score (BVAS).<sup>11</sup> All patients received rituximab therapy over varying periods of time as they received a different number of treatment courses. One treatment course represented a total of four intravenous infusions of rituximab at a dose of 375 mg/m<sup>2</sup>, administered once a week for four consecutive weeks.

### Statistical analysis

The data were analyzed with IBM SPSS version 28.0 software (IBM Corp., Armonk, NY, USA). A descriptive analysis was conducted based on groups of one or several characteristic features and the summative indices relative share and mean. We also performed a diagnostic analysis to test for statistically significant difference in empirically calculated relative shares. The obtained results were further confirmed with alternative assessments of the empirical levels of significance (Clopper-Pearson method), which do not depend on the traditional assessments based on approximations. The obtained means of the investigated clinical and laboratory features were also analyzed; the reported differences were tested for statistical significance through parametric tests (t-test). For assessment of the level of given empirical characteristic features, we used levels based on the assumptions of the distribution of the tested features. The level of significance was set at  $p < 0.05$ .

## RESULTS

In all patients, the diagnosis was confirmed by histopathological findings from appropriately obtained material: biopsy from nasal mucosa (n=13), tissue obtained through bronchoscopy (n=13), renal biopsy (n=48), and skin and muscle biopsy (n=6). The main characteristic features of our patients are shown in Table 1. The mean

**Table 1.** Characteristic features of patients treated with rituximab

Characteristic feature	Treatment outcomes in patients treated with rituximab															
	All patients (n=78)			Improved (n=39)			Remission (n=17)			Stabilization (n=18)			Death (n=4)			
	n	%	Mean	n	%	Mean	n	%	Mean	n	%	Mean	n	%	Mean	p
Age (year)			50.1±13.4			50.3±14.2			45.1±13.7			50.9±12.6			52.7±15.6	0.518
Sex																
Male	37			17			6				11			1		0.837
Female	41			21		4					11		3			
Kidney involvement	62	79.5		16	25.8	3	4.8				10	16.1	2	3.2		0.585
Pulmonary vasculitis	12	15.4		3	25.0	7	58.3			1	8.3		0	0		0.000*
Pulmonary renal syndrome	72	92.3		35	48.6	16	22.2			17	23.6		4	5.6		0.886
Birmingham Vasculitis Activity Score			17.4			17.7			19.3			16.2			16.6	0.358
Creatinine (µmol/L)			310.1			329.6			362.1			302.3			162.0	0.120
Anti-PR3	37	47.4		16	43.2	6	16.2			9	24.3		5	13.5		0.416
Anti-MPO	23	29.5		8	34.8	3	13.0			9	39.1		2	8.7		0.472
ANCA (-)	10	12.8		5	50.0	1	10.0			4	40.0		0	0		0.550
ANCA (+)	67	85.9		34	50.7	16	23.9			14	20.9		3	4.5		0.850

Anti-PR3: Anti-proteinase 3 antibody; Anti-MPO: Anti-myeloperoxidase antibody; ANCA: Antineutrophil cytoplasmic antibody; \* The difference is statistically significant due to remission being achieved significantly more often in patients with pulmonary vasculitis.

**Table 2.** Analysis of treatment regimens

Treatment regimen	n	%
Therapy administered before rituximab		
Corticosteroids	78	100
Cyclophosphamide	41	52.6
Mycophenolate mofetil	9	11.5
Intravenous immunoglobulin	8	10.3
Methotrexate	4	5.1
Plasmapheresis	4	5.1
Therapy administered after rituximab		
Corticosteroids and immunosuppressant (azathioprine)	75	96.2
Cyclophosphamide	3	3.8
Number of rituximab courses		
One	19	24.4
Two	27	34.6
Three	15	19.2
Four or more	17	21.8

BVAS was 17.4. The highest reported BVAS before treatment onset was 30.

### Analysis of treatment regimens

A retrospective analysis of the treatment regimens used in the respective number of patients is presented in Table 2. The primary reason for choosing rituximab over cyclophosphamide in patients previously treated with other agents and treatment modalities (corticosteroids, methotrexate, mycophenolate mofetil, intravenous immunoglobulin, and plasmapheresis) was rapidly progressive kidney damage (RPKD) at the time of diagnosis in 17 (45.9%) patients. The second most common reason was the presence of relapsing or difficult-to-treat infections in five (13.5%) patients or contraindications for cyclophosphamide therapy, such as coronary artery disease with previous myocardial infarction and heart failure.

Cyclophosphamide was most often replaced with rituximab due to an insufficient treatment outcome and a persistence of disease activity in 27 (65.9%) patients. The second most common reason was disease relapse once an

improved condition was reported following cyclophosphamide therapy in six (14.6%) patients. In the other patients, adverse events had been reported over the course of cyclophosphamide therapy (pancytopenia in three [7.3%] patients, thrombotic events in three patients, and elevated liver enzymes in two [4.9%] patients). Additionally, in the three patients in whom rituximab was replaced with cyclophosphamide, two were due to lack of effect and one due to disease relapse while on rituximab.

Organ involvement was another factor influencing the choice of treatment. Of all patients treated with rituximab without preceding cyclophosphamide therapy, 14 (37.8%) had multiple organ involvement (kidney in particular), 12 (32.4%) had involvement of two organ systems, eight (21.6%) of three, two (5.4%) of four, and one (2.7%) of five organ systems. Cyclophosphamide therapy followed by rituximab treatment was most often conducted in patients with multiple organ involvement (78%); eight (19.5%), 13 (31.7%), 10 (24.4%), and one (2.4%) patient had involvement of two,

**Table 3.** Analysis of organ involvement

	Arthritis	Skin	Eyes	Upper airways	Lung	Kidney	Nervous system
RIT (n=37)	13	5	3	12	15	27	2
RIT after CYC (n=41)	14	12	4	21	30	28	7

RIT: Rituximab; CYC: Cyclophosphamide.

three, four, and five organ systems, respectively (Table 3).

### **Analysis of organ involvement**

An analysis of organ involvement of patients treated with rituximab revealed that those managed with rituximab only most often had kidney involvement, while those treated with cyclophosphamide followed by rituximab more often had features of lung and kidney involvement (Table 3). In terms of BVAS, patients who had at least one major renal manifestation (hematuria, a rise in serum creatinine of at least 30%, and renal biopsy findings consistent with glomerulonephritis) without other organ manifestations constituted 38.46% of all patients. Furthermore, 14.10% only had manifestations of lung involvement such as nodules, cavitations, infiltrates, pleurisy, and alveolar hemorrhage. Pulmonary renal syndrome (PRS) was reported in 39.73%. Remission was achieved in 17 (21.8%) patients.

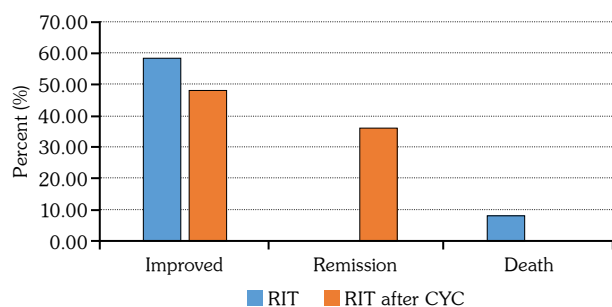
Of patients with renal vasculitis treated with rituximab (a total of 62 patients), 44 (71%) had proteinuria, 54 (88%) had hematuria, and 51 (82.3%) had RPKD. The highest number of patients was reported in the group with advanced (Stage 4) kidney damage (18 [29%] patients), and initial (Stage 1) kidney damage was observed in 17 (27.4%) patients. The mean value of serum creatinine was 310.1  $\mu\text{mol/L}$ . The mean value of proteinuria was 1.32 g/L. In this group of isolated kidney involvement, we noted a good treatment outcome; 25.8% improved, and 4.8% achieved remission. Survival rates were also high in this group, with only two deceased patients. In two-third of cases, serum creatinine levels showed a tendency to decrease after rituximab treatment; in one-third, it reached normal levels. In one-third of cases, creatinine levels did not improve. Over the course of rituximab treatment, four patients started chronic dialysis treatment. In addition, two-third of patients with proteinuria had favorable treatment outcomes (one-third had no significant proteinuria after rituximab treatment, and one-third had a decrease in the level of proteinuria). One-third of patients, however, had no change in the level of proteinuria. Finally, favorable outcomes were achieved with regard to hematuria; half of our patients did not have hematuria after rituximab treatment.

Forty-two (53.8%) patients treated with rituximab had features of lung involvement. Thirty (38.5%) cases had granulomatous inflammation, while 12 (15.4%) had vasculitic manifestations. Furthermore, 12.8% of patients had isolated lung involvement, 5.1% had isolated pulmonary vasculitis, and 6.4% had cavitations. After rituximab treatment, more than half of patients with lung involvement (58.3%) achieved remission; this was a statistically significant difference ( $p=0.0000$ ) compared to other organ manifestations. In addition, 25% improved, and there were no deceased patients. Of the four patients with isolated pulmonary vasculitis, one achieved remission, one improved, and two were stabilized. Of the five patients with cavitations, three achieved remission, one improved, and one had no improvement from the conducted treatment.

In addition, 25.6% of patients had PRS. Almost half of them (48.6%) improved after rituximab treatment, and in 22.2%, full remission was achieved. However, that was also the group with the highest number of deceased patients (5.6%).

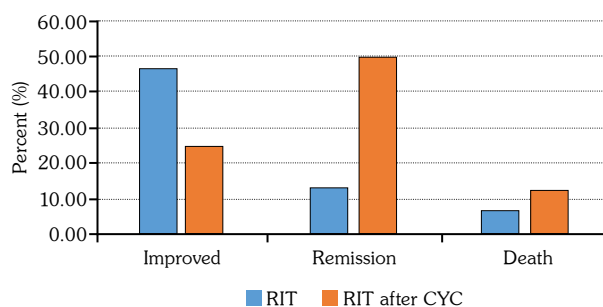
### **Analysis of ANCA presence**

Of patients included in the present study, 85.9% had ANCA before the onset of rituximab treatment. The mean value of ANCA was 8.32 times higher than the reference range. We noted that 50.7% of ANCA-positive patients improved after rituximab treatment. The percentage of improved ANCA-negative patients was 50%. Of 67 ANCA-positive patients treated with rituximab, only 12 (17.9%) remained positive, while in the remaining 82.1%, ANCAs were reported as negative. Of the 12 ANCA-positive patients, five (41.7%) had anti-MPO, and four (33.3%) had anti-PR3; in three cases, ANCA specificity was not examined. Of patients without immunological response, two had clinical improvement; the other 10 patients did not improve clinically. Furthermore, our analysis of antibody types revealed that treatment outcomes were more favorable in patients positive for anti-PR3, where a larger portion improved or achieved remission (Figure 1). The group of patients positive for anti-MPO featured a higher number of stabilized patients and deceased patients



**Figure 1.** Analysis of major treatment outcomes (improvement, remission, and death) in anti-PR3-positive patients.

RIT: Rituximab; CYC: Cyclophosphamide.



**Figure 2.** Analysis of major treatment outcomes (improvement, remission, and death) in anti-MPO-positive patients.

RIT: Rituximab; CYC: Cyclophosphamide.

(Figure 2). These differences, however, were not statistically significant.

### Analysis of disease relapse and mortality

Of the patients included in the present study, eight (10.3%) had disease relapse despite improvement after initial administration of rituximab and while being on rituximab maintenance therapy. Of them, four (50%) had GPA with anti-PR3 antibodies, and four had MPA with anti-MPO antibodies. In three patients, antibody positivity was reported before disease relapse. All these patients had additional therapy with low-dose corticosteroids; one patient also took azathioprine. A total of four patients died throughout the follow-up period owing to infections and uncontrolled disease activity. The analysis of deceased patients is presented in Table 4.

### Analysis of adverse events over the course of rituximab treatment

The most frequent adverse events reported herein (apart from intercurrent infections of the upper airways, lungs, and kidneys) were general malaise after infusion in six (7.7%) patients, an allergic reaction in one (1.3%) patient, reactivation of herpes zoster infection in one patient, and weight loss in one patient.

## DISCUSSION

The successful management of AAV has remained a challenging task. Multiple immunomodulatory and immunosuppressive agents have been used in the therapy of these usually severe vasculitides, including mycophenolate mofetil,<sup>12-14</sup> methotrexate,<sup>15</sup> plasmapheresis,<sup>16</sup> and

**Table 4.** Analysis of deceased patients on rituximab treatment

	Patient 1	Patient 2	Patient 3	Patient 4
Diagnosis	GPA	MPA	GPA	MPA
Disease evolution (month)	6	24	16	15
Age (year)	46	51	44	35
Organ involvement	Upper airways, eyes, lungs, kidneys	Lungs, kidneys	Skin, upper airways, eyes, lungs, kidneys	Lungs, kidneys
Rituximab treatment courses	1	1	1	2
Cause of death	Infection, disease activity	Infection	Disease activity	Disease activity
Period between last rituximab dose and death occurrence (month)	4	1	6	10

GPA: Granulomatosis with polyangiitis; MPA: Microscopic polyangiitis.

intravenous immunoglobulin.<sup>17</sup> The available data on groups of patients treated with rituximab in the literature include more than 250 patients.<sup>6,7,18-22</sup> In the present study, we included and analyzed a total of 78 patients. We found that the most frequent reason for substituting cyclophosphamide with rituximab was the insufficient therapeutic outcome and persistent disease activity. The second most common reason was disease relapse after initial improvement achieved with cyclophosphamide therapy. The adverse events of cyclophosphamide therapy that necessitate a change in therapy and are reported herein include pancytopenia, elevated liver enzymes, and thrombotic events. Most often, rituximab was started as a first-line therapy without preceding use of cyclophosphamide in younger patients and in case of RPKD at the time of diagnosis, which is consistent with previous reports.<sup>7,18</sup> Other common reasons included relapsing or difficult-to-treat infections or contraindications for cyclophosphamide therapy, such as coronary artery disease with previous myocardial infarction and heart failure.

The results of the present study reveal that the number of patients who improved or achieved remission was significantly higher than those with a stabilized disease, worsening disease, or the deceased. Furthermore, our data show that rituximab treatment has a positive impact on all renal symptoms (serum creatinine levels, proteinuria, and hematuria) and a favorable treatment outcome in patients with isolated lung involvement. These findings support the earlier observations of Stone et al.<sup>6</sup> In addition, nearly half of patients with PRS improved with rituximab, and remission was achieved in more than one-fifth; however, that was the group with the highest percentage of deceased patients.

As a whole, 21.8% of all patients included in the present study who were treated with rituximab had a very good response to the therapy and achieved full remission, which is a smaller percentage compared to data from the German registry, where full remission was achieved in 40% of cases.<sup>20</sup> Full remission was achieved more often in other previous reports: 63% of cases as described by Stone et al.,<sup>6</sup> and a remarkable 75% (12 out of 16 cases of previously refractory AAV) as reported by Wendt et al.<sup>22</sup> Improvement or partial remission was observed in 50% of our

patients, which is similar to the number reported in the German registry (52.7%).<sup>20</sup> Contrasting results were noted in the study of Holle et al.<sup>23</sup> in patients with GPA refractory to previously conducted therapy, where remission was achieved in 9.3% of cases, while a favorable treatment outcome was documented in 61.3% of cases.

Comparing the two treatment strategies (rituximab without cyclophosphamide and rituximab as a second-line therapy after cyclophosphamide), we found that rituximab on its own yielded clinical improvement in a higher percentage of patients with GPA and MPA. However, clinical remission was more often achieved in patients treated with cyclophosphamide prior to rituximab therapy. These findings support the results of the RAVE (Rituximab in ANCA-Associated Vasculitis) trial, along with those reported by previous studies, which concluded that rituximab was not superior to cyclophosphamide in terms of efficacy in the treatment of severe AAV; however, it may be superior in relapsing disease.<sup>6,7,19</sup> In addition, a similar outcome and safety profile was reported when comparing the two treatment regimens in AAV with renal involvement.<sup>24</sup> The current treatment recommendations outlined by the ACR favor rituximab over cyclophosphamide for remission induction, as well as in cases of disease relapse in subjects who had not previously received rituximab.<sup>25</sup>

Rituximab's main therapeutic action stems from its impact on B cells, which leads to B cell depletion. According to the data of Jones et al.,<sup>7,19</sup> all patients become ANCA negative after rituximab treatment. These data differ from the results of Stone et al.,<sup>6</sup> who reported that only 47% became ANCA negative after treatment; the number was a bit higher for patients with anti-PR3 (50% of whom became negative), while of those with anti-MPO, 40% became negative. Comparing these reports with the findings in the present study, we noted a few differences. 85.9% of our patients were ANCA-positive before the onset of rituximab treatment. Following treatment, ANCA became negative in 82%. Of the remaining ANCA-positive patients (12 in total), five (41.7%) had anti-MPO, four (33.3%) had anti-PR3, and in three patients, ANCA specificity was not examined. Of patients without immunological response, two had clinical



improvement; the other 10 patients did not improve clinically, which indicates that clinical activity correlated with immunological activity in patients with AAV included in the present study. These findings do not support the data from the study of Stone et al.,<sup>6</sup> where ANCA becoming negative was not associated with remission achievement.

A recent study reported several important clinical and histopathological associations affecting outcomes in AAV.<sup>26</sup> The authors found that ear, nose, and throat involvement was more frequent in anti-PR3-positive subjects, while anti-MPO-positive ones presented with more severe proteinuria, higher serum creatinine levels, and lower estimated glomerular filtration rate. Furthermore, they established that a five factor score (FFS) >2 at diagnosis was associated with presence of poor histopathological findings, such as crescentic, mixed, and sclerotic lesions on renal biopsy, gastrointestinal involvement, anti-MPO, and a decline in annual estimated glomerular filtration rate. It is worth noting that this study found that a higher serum creatinine level was the most important predictor factor for renal prognosis in AAV.

When analyzing antibody types, we found that a more favorable treatment outcome was observed in anti-PR3-positive patients (a higher portion of these patients either improved or achieved remission) than in anti-MPO-positive patients (where the number of stabilized and deceased patients was higher). According to the data from the GRAID (German Registry of Autoimmune Disease) published in 2012, out of 58 patients treated with rituximab, only four (6.9%) died, which is comparable to the number of deceased patients reported in the present study (four out of 78 [5.13%]).<sup>20</sup>

Disease relapse was reported in eight patients who improved after the initial administration of rituximab or who had rituximab maintenance therapy; four were diagnosed with GPA and were positive for anti-PR3, and four were diagnosed with MPA with positive anti-MPO. In three patients, antibodies became positive before the relapse. Adverse events documented over the course of rituximab treatment were rare; we had six patients with adverse infusion reactions, one patient with the reactivation of a latent herpes zoster infection, and one patient with an allergic

reaction. These data are consistent with those reported in previous studies.<sup>6,7,19,20</sup>

There are several limitations to our study that should be noted. First, the number of patients was relatively low, and the duration of treatment and follow-up differed. Second, the treatment regimen and concomitant therapy did not follow a given protocol but were subject to the decision of the respective attending physician and the patient's overall condition. Third, the patients included in the present study were enrolled from a single center. Finally, patient inclusion was based on the choice of treatment, which had sometimes been limited by the cost of therapy.

In conclusion our results confirmed that rituximab treatment in patients with AAV leads to clinical improvement, and it was well tolerated in the examined cohort. These data further support the use of rituximab as an efficient therapeutic option in patients who are difficult to treat, have not improved from previous treatments, or have not tolerated other treatments. The outcome of rituximab treatment is favorable with regard to lung and kidney involvement, as well as multiple organ involvement. Its impact on ANCA is better than the impact of other treatment regimens previously used in clinical practice. ANCA becoming negative following administration of rituximab is associated with a clinical improvement; the efficiency of rituximab appears to be higher in anti-PR3-positive patients.

**Ethics Committee Approval:** The study protocol was approved by the University Hospital 'St. Ivan Rilski' Ethics Committee (date 14.03.2019, no: 29). The study was conducted in accordance with the principles of the Declaration of Helsinki.

**Patient Consent for Publication:** A written informed consent was obtained from each patient.

**Data Sharing Statement:** The data that support the findings of this study are available from the corresponding author upon reasonable request.

**Author Contributions:** Idea/concept: R.R.; Design: T.Y., R.R., I.S.; Control/supervision: I.S.; Data collection and/or processing: T.Y., Y.Z.; Analysis and/or interpretation: T.Y., Y.Z., E.I.T., G.V.; Literature review, writing the article: T.Y., G.K.; Critical Review: R.R., I.S.; References and fundings: T.Y.; Materials: T.Y., E.I.T., G.V.



**Conflict of Interest:** The authors declared no conflicts of interest with respect to the authorship and/or publication of this article.

**Funding:** The authors received no financial support for the research and/or authorship of this article.

## REFERENCES

- Jennette JC, Falk RJ, Andrassy K, Bacon PA, Churg J, Gross WL, et al. Nomenclature of systemic vasculitides. Proposal of an international consensus conference. *Arthritis Rheum* 1994;37:187-92.
- Basu N, Watts R, Bajema I, Baslund B, Bley T, Boers M, et al. EULAR points to consider in the development of classification and diagnostic criteria in systemic vasculitis. *Ann Rheum Dis* 2010;69:1744-50.
- Mukhtyar C, Guillevin L, Cid MC, Dasgupta B, de Groot K, Gross W, et al. EULAR recommendations for the management of primary small and medium vessel vasculitis. *Ann Rheum Dis* 2009;68:310-7.
- Lapraik C, Watts R, Bacon P, Carruthers D, Chakravarty K, D'Cruz D, et al. BSR and BHPR guidelines for the management of adults with ANCA associated vasculitis. *Rheumatology (Oxford)* 2007;46:1615-6.
- Novack SN, Pearson CM. Cyclophosphamide therapy in Wegener's granulomatosis. *N Engl J Med* 1971;284:938-42.
- Stone JH, Merkel PA, Spiera R, Seo P, Langford CA, Hoffman GS, et al. Rituximab versus cyclophosphamide for ANCA-associated vasculitis. *N Engl J Med* 2010;363:221-32.
- Jones RB, Tervaert JW, Hauser T, Luqmani R, Morgan MD, Peh CA, et al. Rituximab versus cyclophosphamide in ANCA-associated renal vasculitis. *N Engl J Med* 2010;363:211-20.
- Weiner GJ. Rituximab: Mechanism of action. *Semin Hematol* 2010;47:115-23.
- Alberici F, Jayne DR. Impact of rituximab trials on the treatment of ANCA-associated vasculitis. *Nephrol Dial Transplant* 2014;29:1151-9.
- Fries JF, Hunder GG, Bloch DA, Michel BA, Arend WP, Calabrese LH, et al. The American College of Rheumatology 1990 criteria for the classification of vasculitis. Summary. *Arthritis Rheum* 1990;33:1135-6.
- Luqmani RA, Bacon PA, Moots RJ, Janssen BA, Pall A, Emery P, et al. Birmingham Vasculitis Activity Score (BVAS) in systemic necrotizing vasculitis. *QJM* 1994;87:671-8.
- Draibe J, Poveda R, Fulladosa X, Vidaller A, Zurberti C, Gomà M, et al. Use of mycophenolate in ANCA-associated renal vasculitis: 13 years of experience at a university hospital. *Nephrol Dial Transplant* 2015;30 Suppl 1:i132-7.
- Jones RB, Hiemstra TF, Ballarin J, Blockmans DE, Brogan P, Bruchfeld A, et al. Mycophenolate mofetil versus cyclophosphamide for remission induction in ANCA-associated vasculitis: A randomised, non-inferiority trial. *Ann Rheum Dis* 2019;78:399-405.
- Sugiyama K, Sada KE, Kurosawa M, Wada J, Makino H. Current status of the treatment of microscopic polyangiitis and granulomatosis with polyangiitis in Japan. *Clin Exp Nephrol* 2013;17:51-8.
- Reinhold-Keller E, de Groot K. Use of methotrexate in ANCA-associated vasculitides. *Clin Exp Rheumatol* 2010;28(5 Suppl 61):S178-82.
- Jayne DR, Gaskin G, Rasmussen N, Abramowicz D, Ferrario F, Guillevin L, et al. Randomized trial of plasma exchange or high-dosage methylprednisolone as adjunctive therapy for severe renal vasculitis. *J Am Soc Nephrol* 2007;18:2180-8.
- Jayne DR, Chapel H, Adu D, Misbah S, O'Donoghue D, Scott D, et al. Intravenous immunoglobulin for ANCA-associated systemic vasculitis with persistent disease activity. *QJM* 2000;93:433-9.
- Jayne D. Role of rituximab therapy in glomerulonephritis. *J Am Soc Nephrol* 2010;21:14-7.
- Jones RB, Ferraro AJ, Chaudhry AN, Brogan P, Salama AD, Smith KG, et al. A multicenter survey of rituximab therapy for refractory antineutrophil cytoplasmic antibody-associated vasculitis. *Arthritis Rheum* 2009;60:2156-68.
- Roll P, Ostermeier E, Haubitz M, Lovric S, Unger L, Holle J, et al. Efficacy and safety of rituximab treatment in patients with antineutrophil cytoplasmic antibody-associated vasculitides: Results from a German registry (GRAID). *J Rheumatol* 2012;39:2153-6.
- Lovric S, Erdbruegger U, Kumpers P, Woywodt A, Koenecke C, Wedemeyer H, et al. Rituximab as rescue therapy in anti-neutrophil cytoplasmic antibody-associated vasculitis: A single-centre experience with 15 patients. *Nephrol Dial Transplant* 2009;24:179-85.
- Wendt M, Gunnarsson I, Bratt J, Bruchfeld A. Rituximab in relapsing or refractory ANCA-associated vasculitis: A case series of 16 patients. *Scand J Rheumatol* 2012;41:116-9.
- Holle JU, Dubrau C, Herlyn K, Heller M, Ambrosch P, Noelle B, et al. Rituximab for refractory granulomatosis with polyangiitis (Wegener's granulomatosis): Comparison of efficacy in granulomatous versus vasculitic manifestations. *Ann Rheum Dis* 2012;71:327-33.
- Geetha D, Specks U, Stone JH, Merkel PA, Seo P, Spiera R, et al. Rituximab versus cyclophosphamide for ANCA-associated vasculitis with renal involvement. *J Am Soc Nephrol* 2015;26:976-85.
- Chung SA, Langford CA, Maz M, Abril A, Gorelik M, Guyatt G, et al. 2021 American College of Rheumatology/Vasculitis Foundation guideline for the management of antineutrophil cytoplasmic antibody-associated vasculitis. *Arthritis Rheumatol* 2021;73:1366-83.
- Özçelik G, Sönmez HE, Şahin S, Özağarı A, Bayram MT, Çiçek RY, et al. Clinical and histopathological prognostic factors affecting the renal outcomes in childhood ANCA-associated vasculitis. *Pediatr Nephrol* 2019;34:847-54.