


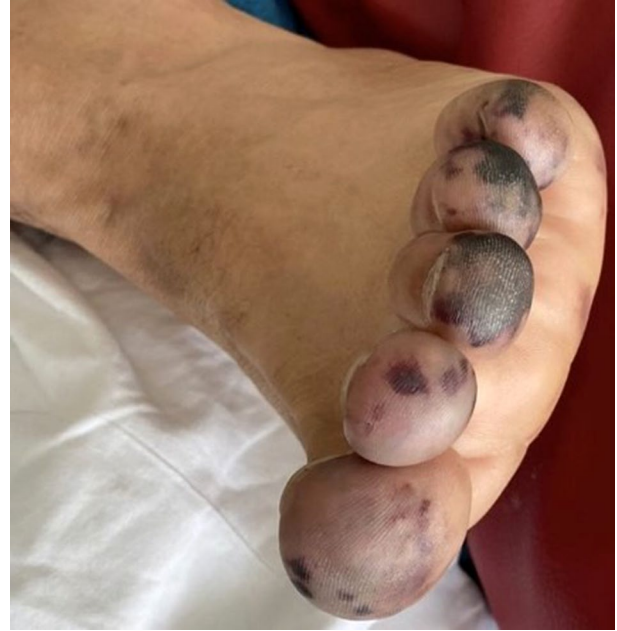## COVID-19-induced digital ischemia in antiphospholipid syndrome

Sadettin Uslu 

*Department of Internal Medicine, Division of Rheumatology, Ömer Halisdemir University  
Bor Physical Medicine and Rehabilitation, Training and Research Hospital, Niğde, Türkiye*

A 37-year-old man, a long-standing history of primary antiphospholipid syndrome (APS), was referred to our department due to a five-day history of skin discoloration in the left foot fingers that were painful. He was diagnosed as having primary APS based on antiphospholipid antibody positivity in repeated measurements at 12-week intervals and deep vein thrombosis of the lower extremity. A detailed clinical history revealed dry cough and myalgia. He also denied smoking or using any medications other than vitamin K antagonist. Physical examination revealed acral ischemic lesions the left foot (Figure 1). Pulses of lower limb were palpable. Doppler sonography of the lower limbs and electrocardiogram showed no abnormalities. Nasopharyngeal swab was positive for novel coronavirus 2019 disease (COVID-19) and chest X-ray showed peripheral consolidations without respiratory distress. The blood test revealed elevated acute phase reactants, D-dimer level, and fibrinogen degradation products. The international normalized ratio (INR) was 2. No venous thromboembolism was found in association, embolic causes were ruled out, and positivity for antiphospholipid antibodies (anticardiolipin immunoglobulin [Ig] M 99 U/mL and IgG >120 U/mL) was confirmed. The patient was followed with the diagnosis of digital ischemia

in the context of COVID-19 and was initiated hydroxychloroquine (HCQ) and his prior treatment was switched for low-molecular-weight heparin



**Figure 1.** Image showing dusky bluish discoloration of the distal parts of the left foot and a clear line of demarcation between the healthy and the ischemic area.

**Received:** February 12, 2022 **Accepted:** July 21, 2022 **Published online:** September 20, 2022

**Correspondence:** Sadettin Uslu, MD. Ömer Halisdemir Üniversitesi Bor Fiziksel Tıp ve Rehabilitasyon Eğitim ve Araştırma Hastanesi, İç Hastalıkları Kliniği, Romatoloji Bölümü, 51700 Bor, Niğde, Türkiye.  
Tel: +90 553 - 483 29 90 e-mail: sadouslu@gmail.com

### Citation:

Uslu S. COVID-19-induced digital ischemia in antiphospholipid syndrome. Arch Rheumatol 2023;38(x):i-ii.

©2023 Turkish League Against Rheumatism. All rights reserved.

This is an open access article under the terms of the Creative Commons Attribution-NonCommercial License, which permits use, distribution and reproduction in any medium, provided the original work is properly cited and is not used for commercial purposes (<http://creativecommons.org/licenses/by-nc/4.0/>).

(LMWH). The lesions and laboratory parameters resolved with treatment after one week.

Antiphospholipid syndrome usually describes an acquired and autoimmune thrombophilia in the presence of persistent antiphospholipid antibodies. Arterial, venous, and small vessels can all potentially be affected by thrombosis, creating a vast set of clinical phenotypes in patients with APS. Digital ischemia is a clinical manifestation of APS.<sup>1</sup> Although COVID-19 mainly manifests as pulmonary involvement, various clinical manifestations such as the limb or digital ischemia can be also seen. The mechanisms of the development ischemia are unclear in COVID-19, but numerous theories have been proposed including hypoxemia, endothelial dysfunction, and inflammation.<sup>2</sup> Antiphospholipid antibodies are known to develop in the setting of viral infections such as COVID-19 and contribute to coagulopathy. The presence of antiphospholipid antibodies has been accepted as one of the mechanisms that cause hypercoagulation during COVID-19. It is, therefore, reasonable to assume that hypercoagulation is an important consequence of inflammation based on the possibility that COVID-19 may trigger the development of an autoimmune condition similar to the APS called “COVID-19-induced APS-like syndrome.”<sup>3</sup> Besides the anticoagulant effect of LMWH, competitive binding activity against COVID-19 and anti-inflammatory properties have been shown to improve the complex picture of coagulopathy.<sup>4</sup> Therefore, it is recommended using LMWH to prevent thrombotic events following COVID-19 in patients who are not contraindicated.<sup>5</sup> Hydroxychloroquine is an anti-malarial drug that has been used in the treatment of autoimmune diseases owing to its anti-inflammatory and immunomodulatory effects. It is also known to be beneficial in preventing thrombotic events in patients with APS.<sup>6</sup> There is scarcely any information in the literature regarding the course of COVID-19, particularly in APS patients. Coagulation disorders have been reported in infections such as COVID-19, which together with the systemic inflammatory

response may lead to antiphospholipid antibodies, knowledge of which would help to management the course of COVID-19 in APS patients.

**Patient Consent for Publication:** A written informed consent was obtained from the patient.

**Data Sharing Statement:** The data that support the findings of this study are available from the corresponding author upon reasonable request.

**Author Contributions:** Preparation and writing of the manuscript; data collection, analysis and interpretation; critical literature review: S.U.; Data collection; approval of the final version of the manuscript: S.U.; Data collection, analysis and interpretation, approval of the final version of the manuscript: S.U.

**Conflict of Interest:** The author declared no conflicts of interest with respect to the authorship and/or publication of this article.

**Funding:** The author received no financial support for the research and/or authorship of this article.

## REFERENCES

1. Miyakis S, Lockshin MD, Atsumi T, Branch DW, Brey RL, Cervera R, et al. International consensus statement on an update of the classification criteria for definite antiphospholipid syndrome (APS). *J Thromb Haemost* 2006;4:295-306.
2. Acherjee T, Bastien B, Rodriguez-Guerra MA, Salman S, Ali N. Digital ischemia as an initial presentation in a COVID-19-positive patient without any significant respiratory symptoms. *Cureus* 2021;13:e14054.
3. Xiao M, Zhang Y, Zhang S, Qin X, Xia P, Cao W, et al. Antiphospholipid antibodies in critically ill patients with COVID-19. *Arthritis Rheumatol* 2020;72:1998-2004.
4. Tandon R, Sharp JS, Zhang F, Pomin VH, Ashpole NM, Mitra D, et al. Effective inhibition of SARS-CoV-2 entry by heparin and enoxaparin derivatives. *J Virol* 2021;95:e01987-20.
5. Tang N, Bai H, Chen X, Gong J, Li D, Sun Z. Anticoagulant treatment is associated with decreased mortality in severe coronavirus disease 2019 patients with coagulopathy. *J Thromb Haemost* 2020;18:1094-9.
6. Schmidt-Tanguy A, Voswinkel J, Henrion D, Subra JF, Loufrani L, Rohmer V, et al. Antithrombotic effects of hydroxychloroquine in primary antiphospholipid syndrome patients. *J Thromb Haemost* 2013;11:1927-9.